

Case Report:

A rare case of bilateral high division of sciatic nerve with unilateral bifid piriformis and its clinical implications

Dr Usha chhabra , Dr Apurba patra , Dr Subhash Kaushal , Dr Harsimarjit Kaur ,
Dr Upasana

Name of the Institute/college: Government Medical College, Patiala (Punjab), India

Corresponding author: Dr Apurba patra

Date of submission: 17 October 2014 ; Date of Publication: 10 December 2014

Abstract:

Sciatic nerve shows many variations in its division, especially its high division. This variation (high division of sciatic nerve) may results in sciatica, nerve injury during deep intramuscular injections in gluteal region, piriformis syndrome, and failed sciatic nerve block in anaesthesia. A very unusual case of two different types of high divisions of sciatic nerve on either side of an adult male cadaver with unilateral divided piriformis muscle was encountered during routine dissection is presented herewith, along with some proposition in available classifications. Knowledge of these variations in course of sciatic nerve may help surgeons and all those who concerns to avoid complication and plan their intervention in a better and more effective way.

Key words: sciatic nerve (SN), common peroneal nerve (CPN), tibial nerve (TN), piriformis muscle, piriformis syndrome (PS)

Introduction:

Sciatic nerve, the continuation of upper band sacral plexus is the thickest nerve of body. Normally it emerges out through the greater sciatic foramen, leaves pelvis and then enters into gluteal region by passing below the piriformis as a single nerve. It then descends between greater trochanter and ischial tuberosity along the back of the thigh, then crosses posteriorly to the obturator internus, gamelli & quadrates femoris muscle. It divides subsequently into two terminal nerves i.e., tibial nerve and common peroneal nerve usually at the lower part of the posterior compartment of thigh¹. But sometimes it divides high, while still in pelvis into its terminal branches that leave pelvis in a number of ways. Accordingly, they are classified into different types in relations to piriformis muscle. High division of

Sciatic nerve is usually unilateral and rarely bilateral.

In this case report, we discuss a very unusual and unique bilateral high division of sciatic nerve and its clinical implications like piriformis syndrome, incomplete block of sciatic nerve during popliteal block anaesthesia, sciatica, coccygo-dynia and muscle atrophy².

Case report:

During routine cadaveric dissection for undergraduate teaching purpose at the Department of Anatomy, Govt. Medical College, Patiala it was found that a 30 year old male cadaver had bilateral high division of sciatic nerve. But it was unusual as it showed different types of variation in divisions of Sciatic nerve on two sides in same cadaver. Division of SN into TN and CPN was within the pelvis bilaterally. However on the right side CPN was

noted to pierce the piriformis as it leave the pelvis to reach gluteal region. On the right side piriformis had a single belly just splitting to allow passage of common peroneal nerve. However, on the left side the piriformis was bifid, referred here as superior and inferior piriformis. The CPN entered gluteal region by passing between two divisions of this piriformis, while TN emerged below lower border of inferior piriformis. The branches of sciatic did not reunite in the gluteal or thigh region. The muscular branches from the tibial component to the hamstring muscles are seen arising from the tibial nerve. The course, branches and relations of both nerves in the popliteal fossa and leg were normal.

Discussion:

During embryological development at the base of the limb bud, the nerves contributing to the lower limb form two plexuses (lumbar and sacral)². Later, as the elements from each of these plexuses grow out into the limb, they are subdivided into dorsal and ventral components, for the dorsal and ventral musculatures.³ The sciatic nerve is formed when the large dorsal component of the sacral plexus (common peroneal nerve) and the ventral component (tibial nerve) move downward close together³. Hence, based on their previously mentioned developmental formation, it is possible that the common peroneal and the tibial divisions of the sciatic nerve separate from each other at different levels from their origins: within pelvis, in the gluteal region, the posterior compartment of the thigh or the popliteal fossa, as observed in this case. Various studies have reported on the level of sciatic nerve division into tibial and common peroneal nerves. It has been observed that Sciatic Nerve usually shows a lot of variations in its division, especially its high division. Smoll pooled results of 18 previous studies and 6,062 cadavers and found that prevalence of this variant in cadavers was 16.9% and in surgical case series was 16.2%⁴. This high division results in sciatica, nerve injury during

deep intramuscular injections in gluteal region⁵, piriformis syndrome, failed SN block in anaesthesia and injury during posterior hip operations.

There are different types of high divisions of SN within pelvis, usually bilateral and if it is unilateral then other side will always remain normal. High division of SN is not rare but rare is to find two different types of high divisions of SN on two sides in same cadaver as in our case. To our knowledge, there is paucity of literature reporting variation of this nature.

Many authors have attempted classification of high divisions of SN. But note that these classifications usually hold good for unilateral or bilateral divisions and can never be properly assigned to our type as it shows two different types of variations on two sides. Hence our attempt to apply these classifications on two sides separately is artificial and it needs a new type of classification in itself⁶. Among the many known classifications, the best known classification is by Beaton and Anson's classification (As cited by Guvencer et al)⁷ who classified all variations under 6 types. Accordingly our case could be classified as Type 2 (Divisions of nerve between and below undivided muscle;) for the right side, whereas we couldn't apply on left side as Beaton mentions only of CPN piercing through piriformis, but doesn't mention of CPN passing between two parts of 'divided piriformis'. Hence this classification should be modified with a new additional classification of Type 7 – divisions of nerve passing between and below divided piriformis muscle. Classification by Okraszewska⁸ was more suitable and we could assign Type IC to right side Type IIB for left side (as it doesn't mention divided or undivided piriformis). These classifications are necessary, especially, for they help surgeons in assessing cause and site of compression of sciatic nerve and accordingly the treatment differs. This will also alert them to be more careful during surgeries. It is usually seen that when

sciatic nerve shows high branching pattern, one of the branch pierces piriformis, but divided piriformis is not usually seen. The latter is said to be a very important cause of piriformis syndrome, as common peroneal nerve passing between two divisions gets compressed and irritated.³ However studies by Machado et al., (100 cases)⁹ and Ugrenovic et al., (200 cases)¹⁰ failed to find even a single divided piriformis. Incidentally, Jawish et al.¹¹ found only one case of divided piriformis among 26 cases selected from 3550 cases complaining of sciatica. Demiryurek et al. also mentioned a case of bilaterally divided piriformis³. Being it Unilateral is still rare¹², as seen in our case on the left side. Diagnosis of unilateral bifid piriformis is very important, as this will help in solving dilemma of neuro-surgeons as to why the symptoms, signs and also the effects of treatment of piriformis syndrome differ on two sides in same person. Mas et al.¹³ have also reported a case of bilateral high division of sciatic nerve but with tibial nerve passing under gemellus superior, unlike the present case wherein common peroneal nerve is passing between two heads of piriformis.

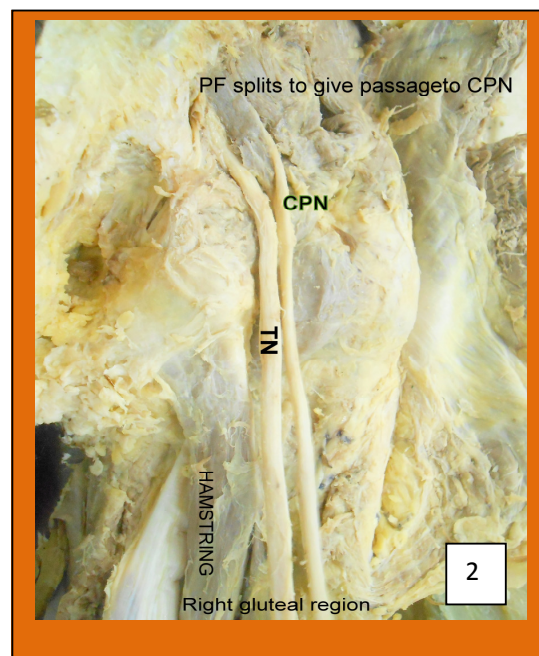
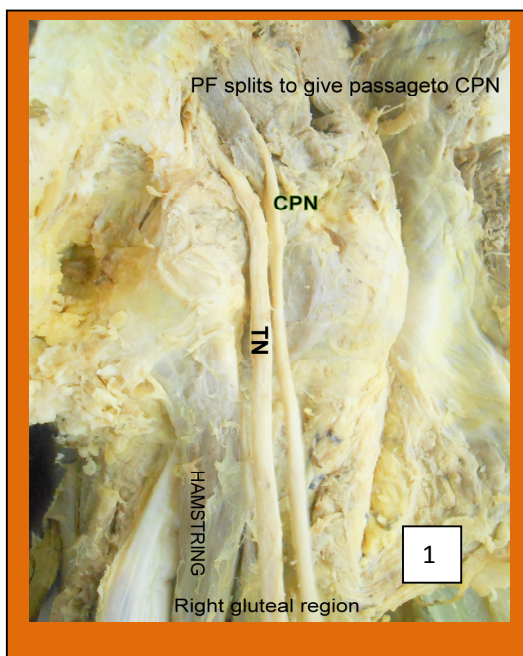
Combinations of these variations – two different types of high divisions of SN on two sides, unilateral divided piriformis makes this as most unique, as well as most interesting among its types.

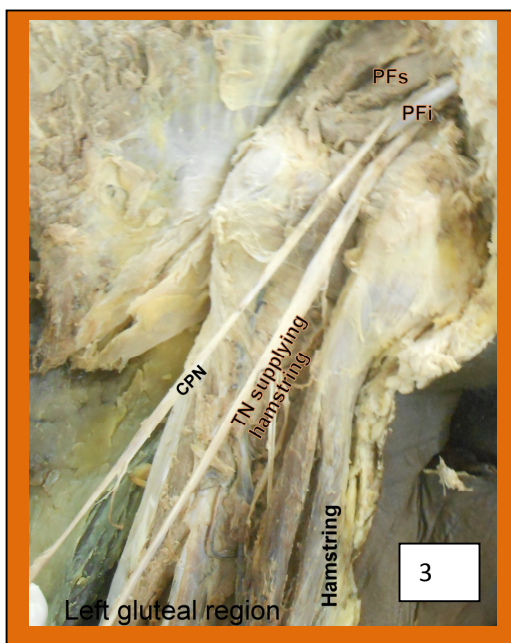Conclusion:

The knowledge of anatomical relationship between piriformis muscle and sciatic nerve is of utmost importance for surgeons, as this is the area of frequent surgical manipulation. Each variation of sciatic nerve in relation to the piriformis muscle has different case specific presentation. A thorough knowledge of different variations will help surgeon to be careful, and plan accordingly during various surgical interventions and management of this region. Radiologist should repeat MRI on other side, as there can be differences on two sides. This knowledge is also very important for nurses and junior residents to prevent hazards of deep intramuscular injection in gluteal region.

Acknowledgement:

We would like to thank all the staff working in the department of anatomy, government medical college, Patiala for their valuable support during the work.





References:

1. Williams PL, Bannister LH, Berry MM, Collins P, Dyson M, Dussek JE et al. Gray's Anatomy. 38th ed. Edinburgh: Churchill Livingstone; 1995. p. 1284.
2. Babinski MA, Machado FA, Costa WS. A rare variation in the high division of the sciatic nerve surrounding the superior gemellus muscle. *Eur J Morphol* 2003;41:41-2.
3. Demiryurek D, Bayramoglu A, Erbil M, Aldur MM, Mustafa ES. Bilateral divided piriformis muscle together with the high division of the sciatic nerve. *Gazi Med J* 2002;13:41-4
4. Smoll NR. Variations of the piriformis and sciatic nerve with clinical consequence: a review. *Clin Anat* 2010; 23: 8–17.
5. Gonzalez P, Pepper M, Sullivan W, Akuthota V. Confirmation of needle placement within the piriformis of a cadaveric specimen using anatomic landmarks and fluoroscopic guidance. *Pain Physician* 2008; 11: 327–331.
6. Khan YS, Khan TK: A rare case of bilateral high division of sciatic nerve (of different types) with unilateral divided piriformis and unusual high origin of genicular branch of common fibular nerve. *IJAV* 2011;4:63–6.
7. Guvencer M, Iyem C, Akyer P, Tetik S, Naderi S. Variations in the high division of the sciatic nerve and relationship between the sciatic nerve and the piriformis. *Turk Neurosurg* 2009;19:139–144.
8. Okraszewska E, Migdalski L, Jedrzejewski KS, Bolanowski W. Sciatic nerve variations in some studies on the Polish population and its statistical significance. *Folia Morphol (Warsz)* 2002;61(4):277-82
9. Machado FA, Babinski MA, Brasil FB, Favorito LA, Abidu-Figueiredo M, Costa MG. Anatomical variations between sciatic nerve and piriform muscle during fetal period in human. *Int J Morphol* 2003;21:29-35.
10. Ugrenovic S, Jovanovic I, Krstic V, Stojanovic V, Vasovic L, Antic S et al. The level of the sciatic nerve division and its relations to the piriform muscle. *Vojnosanit Pregl* 2005;62:45–9.

11. Jawish RM, Assoum HA, Khamis CF. Anatomical, clinical and electrical observations in piriformis syndrome. *J Orthop Surg Res* 2010;5:3.
12. Arifoglu Y, Surucu HS, Sargon MF, Tanyeli E, Yazar F. Double superior gemellus together with double piriformis and high division of sciatic nerve. *Surg Radiol Anat* 1997;19:407-8.
13. Mas N, Ozeksi P, Ozdemir B, Kapakin S, Sargon MF, Celik HH et al. A case of bilateral high division of the sciatic nerves, together with a unilateral unusual course of the tibial nerve. *Neuroanatomy* 2003;2:13-5.